

Superior Laryngeal Nerve Identification and Preservation in Thyroidectomy

Michael Friedman, MD; Phillip LoSavio, BS; Hani Ibrahim, MD

Background: Injury to the external branch of the superior laryngeal nerve (EBSLN) can result in detrimental voice changes, the severity of which varies according to the voice demands of the patient. Variations in its anatomic patterns and in the rates of identification reported in the literature have discouraged thyroid surgeons from routine exploration and identification of this nerve. Inconsistent with the surgical principle of preservation of critical structures through identification, modern-day thyroidectomy surgeons still avoid the EBSLN rather than identifying and preserving it.

Objectives: To describe the anatomic variations of the EBSLN, particularly at the junction of the inferior constrictor and cricothyroid muscles; to propose a systematic approach to identification and preservation of this nerve; and to define the identification rate of this nerve during thyroidectomy.

Materials and Methods: A retrospective review of thyroid lobectomies and total thyroidectomies performed between 1978 and 1997 was carried out. A total of 884 patients were included, with 1057 EBSLNs explored. Intraoperative findings of identification of the EBSLN were

recorded and compared on an annual basis for both benign and malignant disease. Overall results were also compared with those found in previous series identified through a 50-year literature review.

Results: The 3 anatomic variations of the distal aspect of the EBSLN as it enters the cricothyroid were encountered and are described. The total identification rate over the 20-year period was 900 (85.1%) of 1057 nerves. Operations performed for benign disease were associated with higher identification rates (599 [86.1%] of 696) as opposed to those performed for malignant disease (301 [83.4%] of 361). Operations performed in recent years have a higher identification rate (over 90%).

Conclusions: Understanding the 3 anatomic variations of the distal portion of the EBSLN and its relation to the inferior constrictor muscle allows for high rates of identification of this nerve. The EBSLN should be explored during thyroid surgery and identification is possible in most cases. Preservation of the EBSLN maintains optimal function of the larynx.

Arch Otolaryngol Head Neck Surg. 2002;128:296-303

From the Department of Otolaryngology and Bronchoesophagology, Rush-Presbyterian-St Luke's Medical Center (Drs Friedman and Ibrahim and Mr LoSavio), and the Division of Otolaryngology, Advocate Illinois Masonic Medical Center (Drs Friedman and Ibrahim), Chicago, Ill.

THE CLINICAL significance of the superior laryngeal nerve (SLN) has been clearly overshadowed by emphasis on the recurrent laryngeal nerve.

The principles of head and neck surgery are based on identification and preservation as opposed to avoidance of important structures. These principles would set identification and preservation of the SLN as standard in all thyroid surgery. The nerve is clearly at risk, and injury is clearly detrimental to the patient. Despite these facts, the SLN is not routinely identified by most surgeons, and some physicians have presented studies to justify this apparent inconsistency in optimal surgery.¹⁻³

Many articles deal with the variable anatomy of the superior laryngeal nerve.³⁻¹¹

Most of these articles focus on the anatomic relationship of the SLN to the superior thyroid artery. They discuss the likelihood of the SLN being at risk for injury and the probability of identifying the SLN during surgery; they suggest that the SLN often cannot be identified. Very little has been written on the anatomy of the distal portion of the SLN as it enters the cricothyroid muscle.³

This study was undertaken to review the experience of the senior surgeon (M.F.) with the SLN in more than 1000 thyroid lobectomies over a 20-year period. The study reviews the anatomy of the distal end of the SLN as it relates to the practical aspect of surgical identification. It also reviews the percentage of cases in which the SLN was actually identified. It presents a reliable technique for practical identification and

MATERIALS AND METHODS

This nonrandomized retrospective study reviews a 20-year experience of thyroid lobectomies from the year 1978 to 1997. The charts of all patients who underwent thyroidectomy and/or lobectomy were reviewed to assess if the external branch of the SLN (EBSLN) was identified and preserved or not identified at surgery. Cases were categorized into benign or malignant as determined by pathology reports at the time of surgery, and the percent identification was compared for each calendar year. Overall, 884 patient cases were reviewed with a total of 1057 EBSLNs put at risk (696 nerves [65.8%] in cases with benign tumors and 361 nerves [34.2%] with malignant tumors). A full literature search was performed on the OVIDWEB-MEDLINE database looking for all relevant articles since 1950 that comment on the identification, preservation, anatomy, surgical technique, and injury rate to the EBSLN.

SURGICAL ANATOMY

The SLN is classically described as originating from the middle of the nodose ganglion. In addition, it receives contributions from the superior cervical sympathetic ganglion. Its path of descent initially begins posteriorly and proceeds medially to the internal carotid artery where it bifurcates into an internal (sensory and autonomic) and external laryngeal branch (motor).^{12,13} The internal branch proceeds to pierce the thyrohyoid membrane with the superior laryngeal artery and subsequently divides into an upper and lower branch. The external branch continues to travel inferiorly, passing superficially to the inferior constrictor and then piercing it to finally reach the cricothyroid muscle.¹² While this level of description can suffice for the nonsurgical observer, more detailed descriptions have helped to elucidate the variations in the anatomy of the EBSLN to aid the surgeon operating in this area.³⁻¹¹

This study focused on the anatomy of the EBSLN at its insertion into the cricothyroid muscle. Terminal branches of the EBSLN penetrate the horizontal and oblique bellies of the cricothyroid muscle as well as the inferior constrictor. However, 3 variations have been described for the main trunk of the EBSLN prior to its terminal branching. In the type 1 variation, it runs its whole course superficially or laterally to the inferior constrictor, descending with the superior thyroid vessels until it terminates in the cricothyroid muscle (**Figure 1**). In the type 2 variation, the EBSLN penetrates the inferior constrictor in the lower portion of the muscle (**Figure 2**). In this case it is only partially protected by the inferior constrictor. And finally, the type 3 nerve dives under the superiormost fibers of the inferior constrictor, remaining covered by this muscle throughout its course to the cricothyroid muscle (**Figure 3**).

Often the SLN is not easily visible, and some authors consider these situations ones of "unidentifiable nerves."¹⁻³ These authors believe that if the course of the distal branch runs under the inferior constrictor muscle (which occurs in 20% of cases³), the nerve is unidentifiable. In fact, we have found that in most of these situations the nerve can be identified by nerve stimulation along the border of the inferior constrictor and the cricothyroid (type 3, Figure 3).

The muscle response of the stimulated nerve is quite different than the response of direct muscle stimulation. Absence of identification by stimulation should direct the surgeon back to the region of the vessels to search for a missed type 1 nerve.

This classification is based on the terminal aspect of the EBSLN and is provided as a practical guide for identification. It does not replace previously described classifications by Kierner et al⁴ and Cernea et al⁵ that focus on the EBSLN and the superior thyroid vessels' relationship. The percentage of patients with anatomy corresponding to 1 of these 3 types has not been studied in detail by us or by other investigators. Lennquist et al³ studied the percentage of their patients with type 3 distribution and found it to be 20%. Although the retrospective review of the data was not detailed enough in that study to identify which type was present in every case, all 3 types were frequently identified.

SURGICAL TECHNIQUE

A previously described systematic approach¹⁴ was used consistently in all of our cases. After raising subplatysmal flaps, care was taken to maintain meticulous hemostasis as the sternohyoid and sternothyroid muscles were individually elevated laterally (**Figure 4** and **Figure 5**). The sternohyoid muscle was elevated laterally up to the hyoid to allow visualization of the sternothyroid muscle insertion into the oblique line of the thyroid cartilage. The sternothyroid muscle was then elevated laterally until the lateral edge of the thyroid gland was reached. The medial edge of the superior attachment of the sternothyroid muscle was transected with a bipolar cautery for a distance of 5 mm (**Figure 6**), which provided better exposure of the inferior constrictor–cricothyroid junction. The horizontal and oblique bellies of the cricothyroid muscle were identified as was the anterior edge of the inferior constrictor.

A disposable nerve stimulator (set on 2 mA) was used to identify the terminal branches of the EBSLN as they enter the cricothyroid bellies. The stimulator was first used directly on the cricothyroid muscle to assess the response of direct muscle stimulation. This helps differentiate muscle stimulation from nerve stimulation. If the EBSLN was identified over the inferior constrictor (type 1, Figure 1), it was followed in a retrograde direction. Identification of the nerve in this location allows for preservation of the nerve. This anatomic variant is usually associated with an EBSLN that crosses the superior thyroid artery at or below the superior thyroid pole. This scenario places the nerve at risk not only during ligation of the superior thyroid vessels but during dissection of the loose areolar tissue adjacent to the superior pole. Routinely, the superior pole vessels and the loose areolar tissue surrounding them are not dissected until the EBSLN is explored. In some cases, the EBSLN can be identified crossing some of the inferior constrictor and then diving under the muscle for a variable distance prior to its insertion in the cricothyroid muscle (type 2, Figure 2). Once this nerve is identified, no further dissection is usually needed.

The EBSLN is considered at risk in each patient until it is identified. The nerve is stimlatable in almost all cases at the junction of the cricothyroid and inferior constrictor muscles. Identification by stimulation assures the surgeon that the nerve is not at risk.

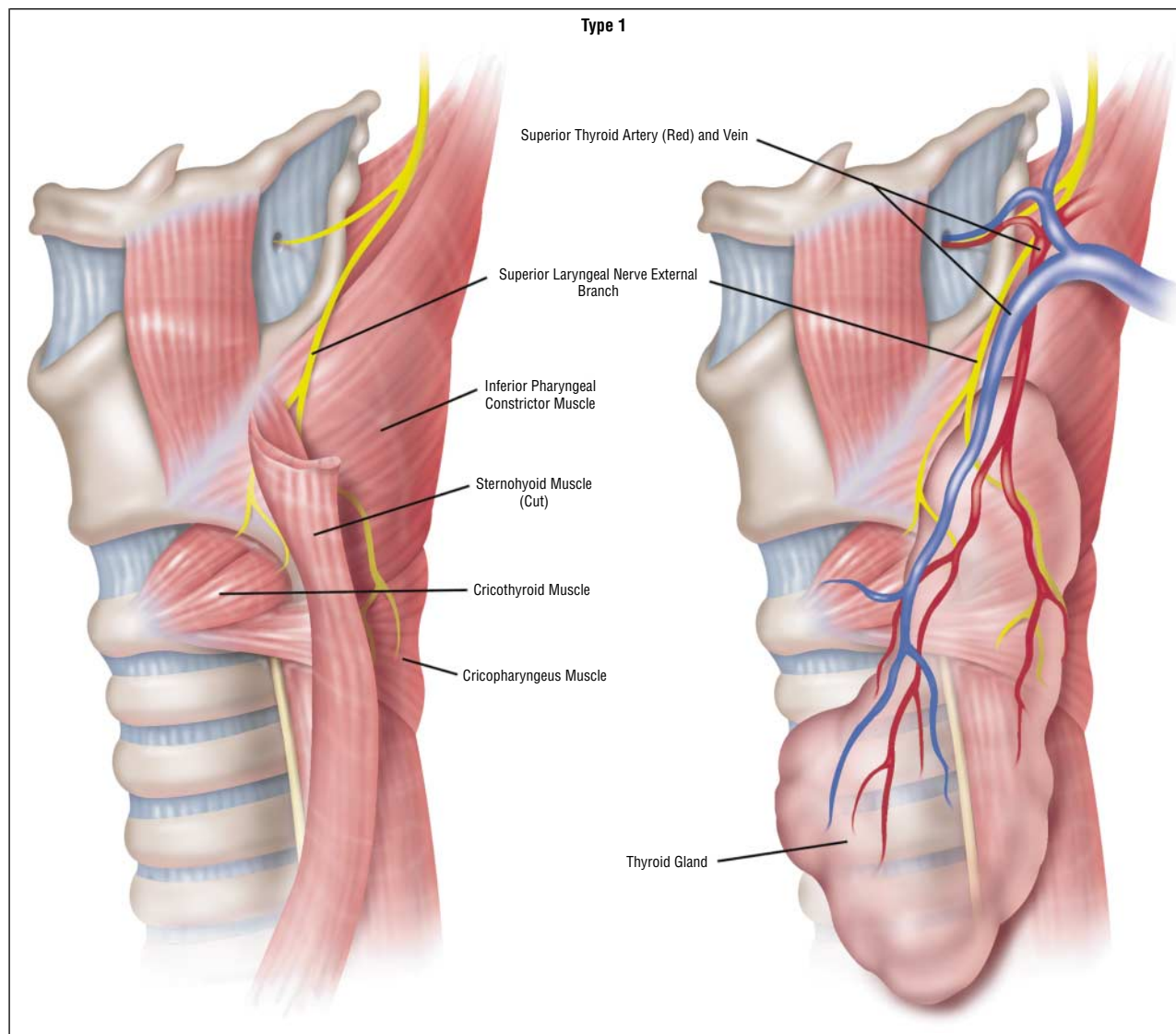


Figure 1. Type 1 anatomic variant: the external branch of the superior laryngeal nerve runs superficially to the inferior constrictor muscle.

preservation of the SLN in thyroid surgery in a high percentage of cases.

RESULTS

Table 1 summarizes the results of our study. The identification and preservation rate in 884 patients over 20 years, with a total of 1057 nerves at risk, was 85.1% (900/1057). The identification rates were calculated annually from 1978 to 1997. In later years, the use of stimulation to identify the EBSLN covered by the inferior constrictor helped increase the identification rate from 75% in 1978 to 90% in 1997.

COMMENT

Identification of the EBSLN has become a standard practice in all thyroid lobectomies performed by one of us (M.F.). The aforementioned technique of distal identification at the inferior constrictor–cricothyroid

junction has resulted in an average identification rate of 85.1% over the past 20 years, with recent years demonstrating a higher than 90% success rate. Although the absence of patient complaints and abnormal laryngeal examination findings postoperatively allowed the authors to assume a lower injury rate, no specific studies were routinely performed to confirm this assumption. The purpose of the study was not to establish an injury rate but to review the anatomy and establish the identification rate attainable with routine thyroid surgery.

The importance of avoiding injury to the EBSLN should not be understated when discussing the sequelae of complications during thyroid surgery. Paralysis of the SLN can be significant to those whose career depends heavily on full range of voice. One of the earliest reported cases goes back to 1935 when famous opera singer Amelita Galli-Curci suffered injury to her EBSLN after thyroid surgery with devastating consequences.¹⁵

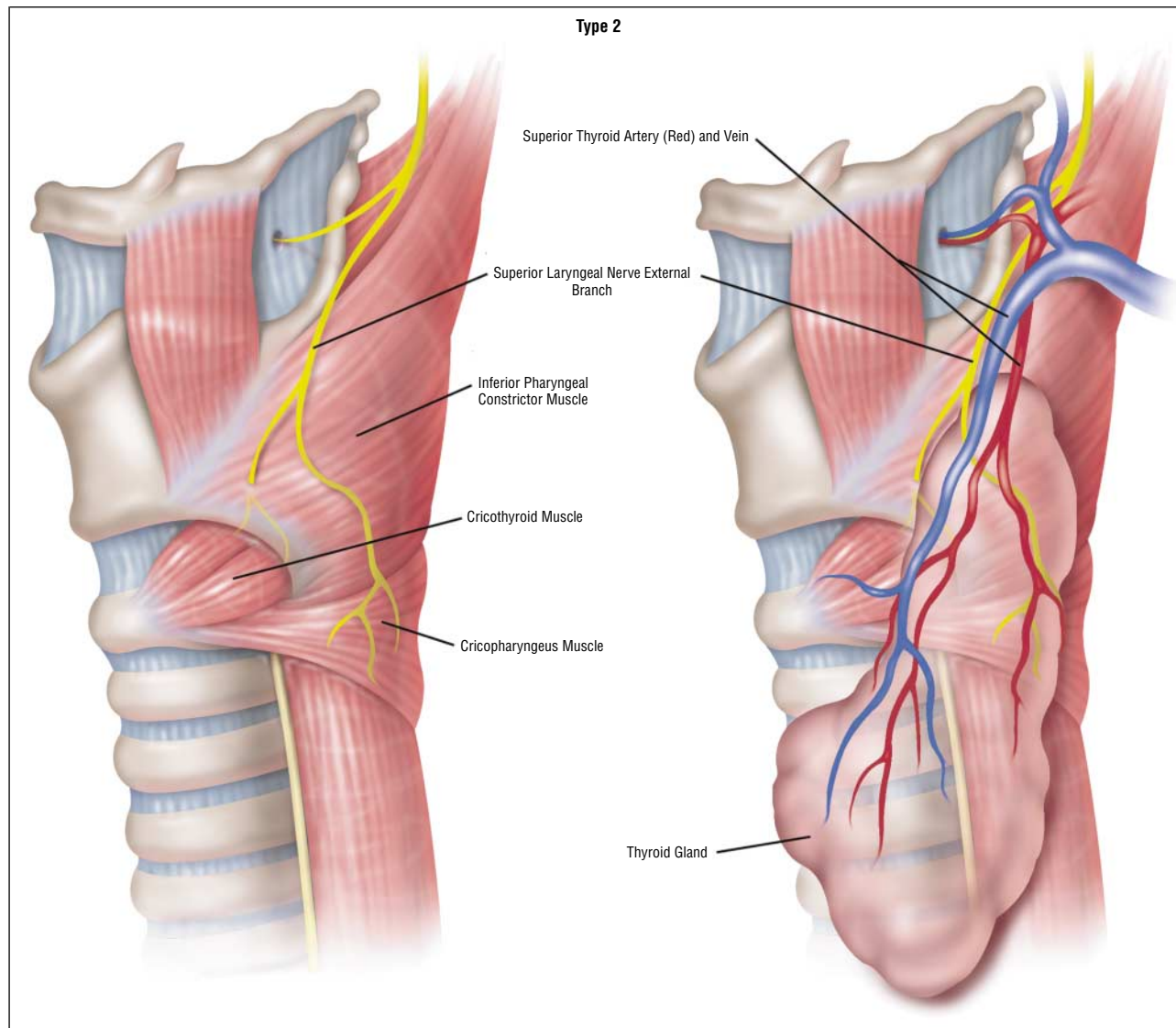


Figure 2. Type 2 anatomic variant: the external branch of the superior laryngeal nerve dives deep to the inferior constrictor muscle, approximately 1 cm proximal to the inferior constrictor–cricothyroid junction.

Damage to the nerve can manifest as ipsilateral paralysis to the cricothyroid muscle as demonstrated by electromyography (EMG) and fiberoptic stroboscopic laryngoscopy.^{16,17} Clinical symptoms may present as a hoarse, breathy voice, increased throat clearing, vocal fatigue, or diminished vocal frequency range, especially in regard to raising pitch. The clinician may find signs of bowing and inferior displacement of the affected cord on examination.¹⁶ Two anatomic studies on cadavers^{6,7} using special staining to map out nerve distributions and patterns around the larynx have demonstrated communicating nerves between the EBSLN and the recurrent laryngeal nerve. They suggest that the EBSLN may contribute significant innervation to other muscles beyond the cricothyroid adding to the evidence of this nerve's importance.

Identification and injury rates have varied greatly across different studies, with identification rates ranging

from 33% to 93%, while injury rates have been reported between 0% and 58%^{1-3,8,16,18-21} (**Table 2**). The variation in results is partially explained by the nonconcordance of surgical techniques used by different physicians. In many circumstances, inaccuracy of evaluation techniques has also most likely resulted in underreported EBSLN injury rates. Jansson et al¹⁸ reported that partial SLN lesions could not be diagnosed reliably based on indirect laryngoscopy or voice symptoms. They pointed to EMG as a much more definitive method of making a diagnosis. Unfortunately, many studies to date have not used EMG when reporting injury rates.^{1-3,19,20}

Another important factor to consider is that published injury rates may not be applicable to the average surgeon in every circumstance. As demonstrated by Cernea et al,⁸ training level played a significant role in correlating with injury rates, with residents recording a 28% injury rate and the senior author (Claudio R. Cernea,

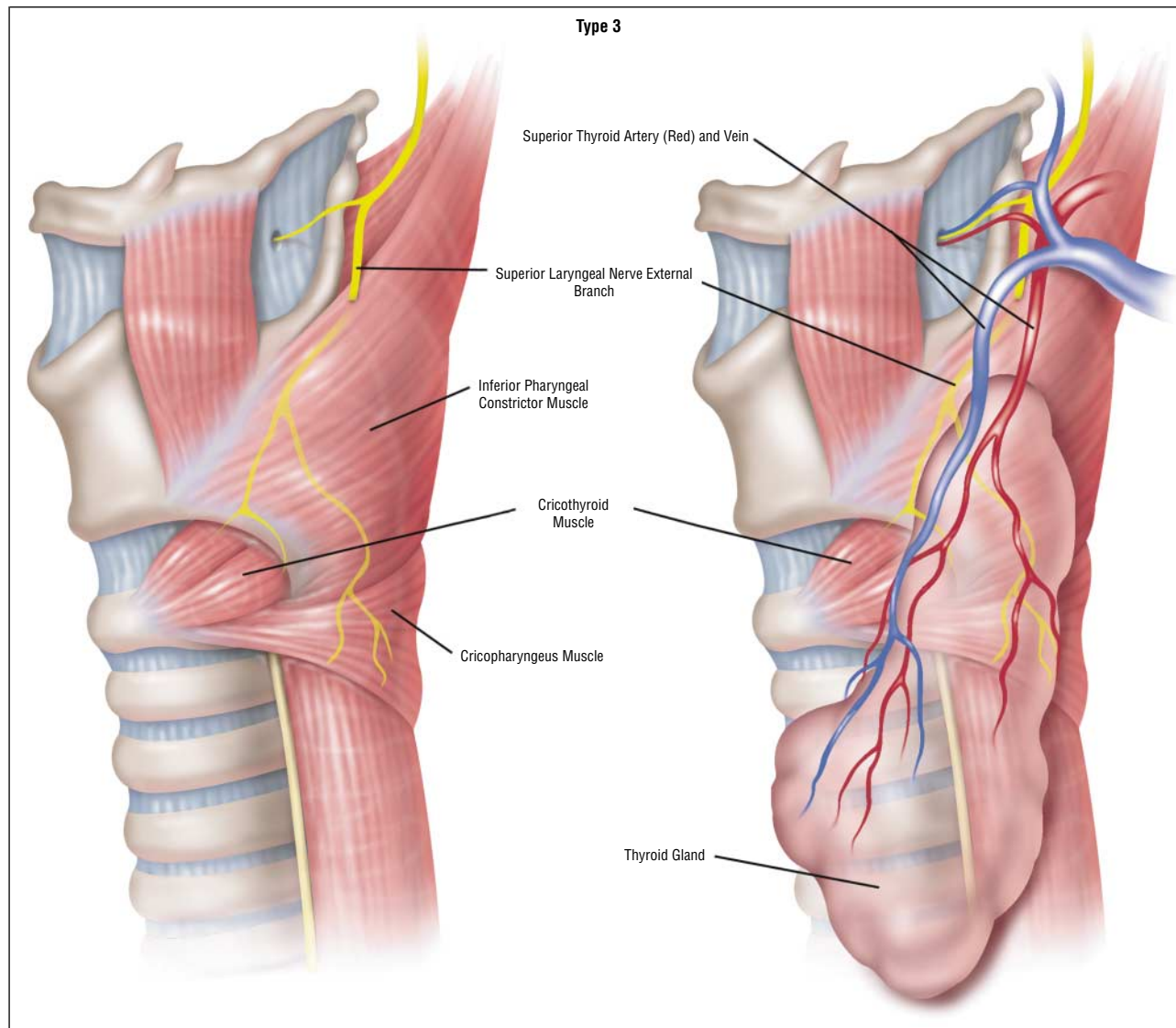


Figure 3. Type 3 anatomic variant: the external branch of the superior laryngeal nerve runs deep to the inferior constrictor muscle.

MD) reporting only a 12% rate. Lore et al² argue that it is not necessary to avoid the nerve to avoid injuring it. They point out that many of the existing studies show similar rates of injury whether the nerve is located or not. In their own series they report an extremely low injury rate. In spite of this, it is an accepted surgical principle that identification is the key to preservation of structures at risk.

Variability in the anatomy of the EBSLN as it relates to the superior thyroid artery has been studied in detail.^{3-5,8-11} Cernea et al⁵ were among the first to describe a specific classification system (types 1, 2a, or 2b); they found the percentage of each pattern to vary among patients with either small or large goiters owing to the alteration in the anatomic arrangement that takes place with enlargement of the thyroid gland. Kierner et al⁴ revisited this subject with cadaver studies and refined the nomenclature, taking into account the cases that Cernea and colleagues⁵ labeled as “not identified” (**Table 3**). Type 2b (which correlates with

our described type 1 pattern) is at the highest risk during surgery, with the categories in which the nerve crosses relatively high to the upper thyroid pole being at considerably less risk of iatrogenic injury. This fact, however, should not preclude one from identifying all circumstances in which the nerve presents itself. Indeed, the rate of 2b variants is significantly increased in cases of disease caused by superior displacement of the upper thyroid pole.⁵ Cernea et al⁵ reported a difference of 54% vs 14% in cases of large and small goiters, respectively. When the surgeon ligates the superior pole vessels and has not identified the EBSLN, it cannot be assumed that it is a high-crossing variant and therefore not at risk. Negative findings could always prove to be a case of a 2b nerve that has yet to be successfully located. At the same time, it is unreasonable for one to expand the surgical field superiorly to unquestionably identify these other variants higher in the neck. We propose our system that concentrates not on the superior thyroid vessels, but

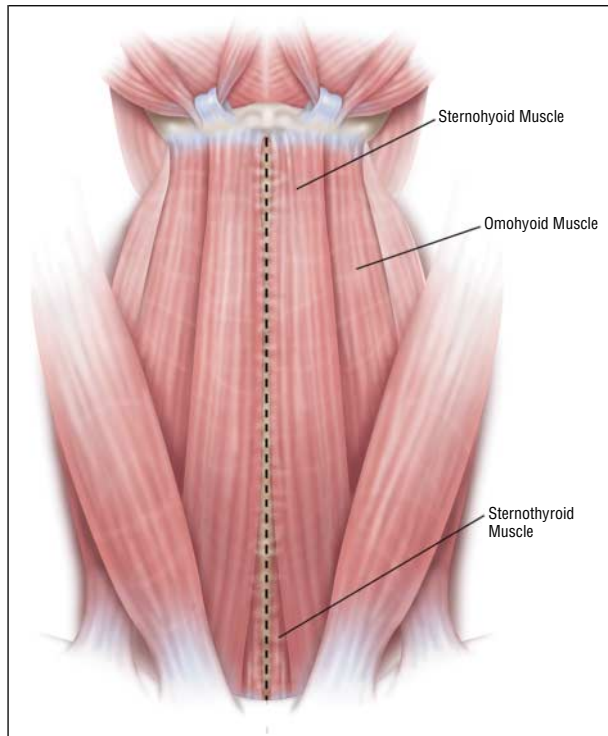


Figure 4. Strap muscles.

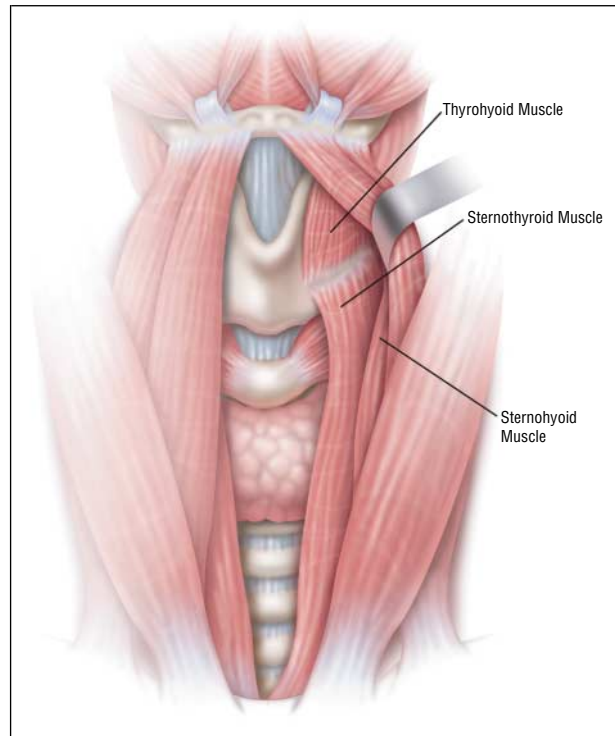


Figure 5. The sternohyoid muscle is dissected laterally up to the hyoid bone to allow visualization of the sternothyroid muscle and its attachment to the oblique line.

on the presentation of the nerve in the inferior constrictor–cricothyroid junction with subsequent retrograde dissection and preservation.

Only the clinical and anatomic studies of this region by Lennquist et al³ have described in detail the relationship of the EBSLN with its entry into the cricothyroid muscle. They point to the fact that in nearly 20% of cases the nerve is buried in the fibers of the inferior pharyngeal constrictor and thus not identifiable without dissection of the fibers. They argue that in these cases where the nerve is covered by constrictor fibers greater than 10 cm proximal to cricothyroid entry, more harm than good will result from a search for the nerve.³ Our technique, however, does not subject the constrictor fibers to a destructive reconnaissance mission because we limit our dissection to the junction between the 2 muscles. Positive identification of the nerve at the junction of the inferior constrictor and cricothyroid muscles can be accomplished in most cases with minimal dissection. This increases the overall identification rate.

In conclusion, preservation of the EBSLN is important for optimal function of the larynx. The nerve is at risk during thyroidectomy, and although injury rates are not clearly established, they do exist. The principles of head and neck surgery dictate that the best way to avoid injury to a structure at risk is by identification and preservation. The EBSLN has not been routinely identified because of conflicting data on the ability and rate of intraoperative identification. This study establishes an identification rate of over 85% based on a simple technique combined with detailed knowledge of the anatomy of the terminal

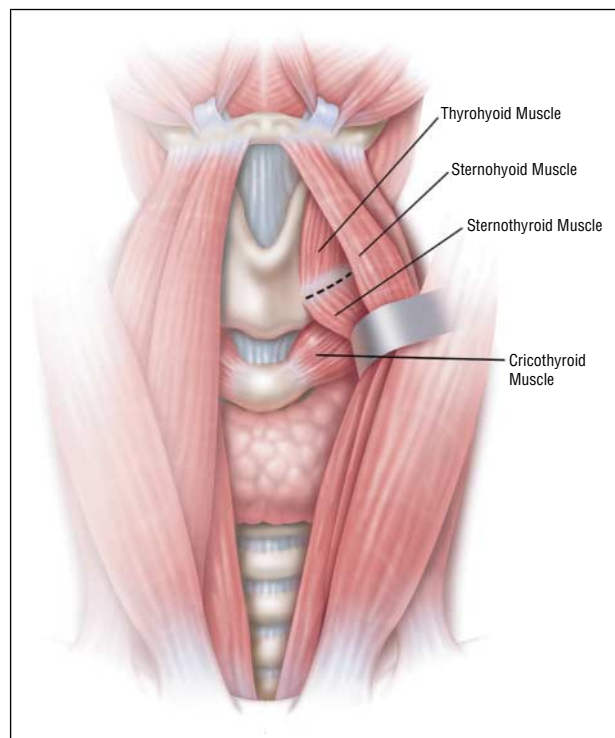


Figure 6. If the inferior constrictor–cricothyroid junction is not clearly visible by retraction of the sternohyoid, the medial 5-mm attachment of the sternohyoid is transected.

branches of the EBSLN. Routine identification and preservation is possible in most thyroidectomy procedures.

Table 1. EBSLN* Identification (ID) and Preservation Rates for Benign and Malignant Disease

Year	No. of Patients	Benign			Malignant		
		No. of Nerves Identified	No. of Nerves at Risk	ID Rate, %	No. of Nerves Identified	No. of Nerves at Risk	ID Rate, %
1978	17	10	12	83.33	6	8	75
1979	26	14	19	73.68	8	11	72.73
1980	29	13	19	68.42	10	14	71.43
1981	43	30	37	81.08	12	15	80
1982	48	32	36	88.89	14	18	77.78
1983	40	30	35	85.71	11	14	78.57
1984	45	30	35	85.71	15	17	88.24
1985	41	26	29	89.66	14	17	82.35
1986	42	26	31	83.87	14	17	82.35
1987	41	31	37	83.78	13	16	81.25
1988	42	27	35	77.14	12	14	85.71
1989	44	32	36	88.89	15	18	83.33
1990	51	34	40	85	16	18	88.89
1991	54	36	43	83.72	17	21	80.95
1992	54	33	40	82.5	24	30	80
1993	49	27	32	84.38	23	28	82.14
1994	54	40	42	95.24	17	18	94.44
1995	51	38	41	92.68	18	20	90
1996	61	48	51	94.12	24	27	88.89
1997	52	42	46	91.3	18	20	90
Total	884	599	696	86.06	301	361	83.38

*EBSLN indicates external branch of the superior laryngeal nerve.

Table 2. Reported EBSLN Identification (ID) and Injury Rates*

Source	Evaluation Method	Surgical Technique	ID Rate, %	Injury Rate, %
Jonas and Bahr ¹	Laryngoscopy, voice evaluation	Neuromonitoring to find nerve	37.8	4.6 (Temporary)
Lore et al ²	Laryngoscopy, questioning	Not necessary to expose nerve	33	7.5 (Permanent)
Teitelbaum and Wenig ¹⁶	EMG, videostroboscopy, questioning	No routine ID of nerve	...	5 (Permanent)
Cernea et al ⁸	EMG, voice evaluation	Nerve stimulator compared with no nerve search done by resident and attending physicians	93	0 (Attending physician, nerve search attempted), 12 (Attending physician, no nerve search), 28 (Resident physician, no nerve search)
Jansson et al ¹⁸	EMG, indirect laryngoscopy, voice evaluation	No routine technique to identify superior laryngeal nerve	...	58 (Temporary)
Lenquist et al ³	Laryngoscopy, questioning	Inspection of distal part of constrictor for nerve but no muscle dissection	72	2.6 (Due to diathermy error)
Lekacos et al ¹⁹	Laryngoscopy	Separately ligate superior pole vessels; no nerve exposure	...	5.6 (High ligation of vessels), 0 (Low ligation of vessels)
Kark et al ²⁰	Laryngoscopy, oscilloscopy, questioning	Looked at nerve ID vs without nerve ID	84	5 (Nerve search attempted), 3 (Nerve search not attempted)
Reeve et al ²¹	Laryngoscopy, voice evaluation	Tried to identify nerve	59	

*EBSLN indicates external branch of the superior laryngeal nerve; EMG, electromyography; and ellipses, not applicable.

Table 3. EBSLN Classification Systems*

Cernea et al ⁴	Kierner et al ⁴	Criteria
Type 1 (68% SG, 23% LG)	Type 1 (42%)	Crosses STA >1 cm above upper pole
Type 2a (11% SG, 15% LG)	Type 2 (30%)	Crosses STA <1 cm above upper pole
Type 2b (14% SG, 54% LG)	Type 3 (14%)	Crosses STA under cover of upper pole
Not described	Type 4 (14%)	Descends dorsal to artery and crosses STA branches immediately above upper pole

*EBSLN indicates external branch of the superior laryngeal nerve; SG, small goiters; LG, large goiters; and STA, superior thyroid artery.

Accepted for publication November 15, 2001.

This study was presented at the annual meeting of the American Head and Neck Society, Palm Desert, Calif, May 16, 2001.

Corresponding author: Michael Friedman, MD, 30 N Michigan Ave, Suite 1107, Chicago, IL 60612 (e-mail: khender213@aol.com).

Reprints: Michael Friedman, MD, Department of Otolaryngology and Bronchoesophagology, Rush-Presbyterian-St Luke's Medical Center, 1653 W Congress Pkwy, Chicago, IL 60612-3833.

REFERENCES

1. Jonas J, Bahr R. Neuromonitoring of the EBSLN during thyroid surgery. *Am J Surg.* 2000;179:234-236.
2. Lore JM, Kokocharov SI, Kaufman S, Richmond A, Sundquist N. 38-Year evaluation of a surgical technique to protect the EBSLN during thyroidectomy. *Ann Otol Rhinol Laryngol.* 1998;107:1015-1022.
3. Lennquist S, Cahlin C, Smeds S. The superior laryngeal nerve in thyroid surgery. *Surgery.* 1987;102:999-1008.
4. Kierner AC, Aigner M, Burian M. The EBSLN: its topographical anatomy as related to surgery of the neck. *Arch Otolaryngol Head Neck Surg.* 1998;124:301-303.
5. Cernea CR, Nishio S, Hojaj FC. Identification of the EBSLN in large goiters. *Am J Otol.* 1995;16:307-311.
6. Wu BL, Sanders I, Mu L, Biller HF. The human communicating nerve: an extension of the EBSLN that innervates the vocal cord. *Arch Otolaryngol Head Neck Surg.* 1994;120:1321-1328.
7. Sanders I, Wu BL, Mu L, Youzhu L, Biller HF. The innervation of the human larynx. *Arch Otolaryngol Head Neck Surg.* 1993;119:934-939.
8. Cernea CR, Ferraz AR, Furlani J, et al. Identification of the EBSLN during thyroidectomy. *Am J Surg.* 1992;164:634-639.
9. Moosman DA, DeWeese MS. The external laryngeal nerve as related to thyroidectomy. *Surg Gynecol Obstet.* 1968;127:1011-1016.
10. Durham CF, Harrison TS. The surgical anatomy of the superior laryngeal nerve. *Surg Gynecol Obstet.* 1964;118:38-44.
11. Cernea CR, Ferraz AR, Nishio S, Dutra A, Hojaj FC, Medina dos Santos LR. Surgical anatomy of the EBSLN. *Head Neck.* 1992;14:380-383.
12. Williams PL, Bannister LH, Berry MM, et al. In: Williams P, Dyson M, Bannister LH, et al, eds. *Gray's Anatomy.* 38th ed. New York, NY: Churchill Livingstone; 1995.
13. Moore KL. *Clinically Oriented Anatomy.* 3rd ed. Baltimore, Md: Williams & Wilkins; 1992.
14. Friedman M, Toriumi DM. Functional identification of the external laryngeal nerve during thyroidectomy. *Laryngoscope.* 1986;96:1291-1292.
15. Eisele DW, Goldstone AC. Electrophysiologic identification and preservation of the superior laryngeal nerve during thyroid surgery. *Laryngoscope.* 1991;101:313-315.
16. Teitelbaum BJ, Wenig BL. Superior laryngeal nerve injury from thyroid surgery. *Head Neck.* 1995;17:36-40.
17. Abelson TI, Tucker HM. Laryngeal findings in SLN paralysis: a controversy. *Otol Head Neck Surg.* 1981;89:463-470.
18. Jansson S, Tisell L, Hagne I, Sanner E, Stenborg R, Svensson P. Partial SLN lesions before and after thyroid surgery. *World J Surg.* 1988;12:522-527.
19. Lekacos NL, Milligos ND, Tzardis PJ, Majiatis S, Patoulis J. The SLN in thyroidectomy. *Am Surg.* 1987;53:610-612.
20. Kark AE, Kissin MW, Auerbach R, Meikle M. Voice changes after thyroidectomy: role of the external laryngeal nerve. *BMJ.* 1984;289:1412-1415.
21. Reeve TS, Coupland GAE, Johnson DC, Buddee FW. The recurrent and external laryngeal nerves in thyroidectomy. *Med J Aust.* 1969;1:380-382.